



The effect of routine lymphadenectomy of the hepatic basin on the duration of the liver resection due to colorectal carcinoma metastases

Uticaj rutinske limfadenektomije hepatičnog sliva na trajanje resekcije jetre zbog metastaza kolorektalnog karcinoma

Dragan D. Basarić^{*†}, Ivan Soldatović^{**‡}, Nebojša Lekić^{**†}, Vladimir Djordjević[†], Ljubomir Djurašić[§], Marjan Micev^{*||}

University of Belgrade, ^{*}Faculty of Medicine, Belgrade, Serbia; Clinical Centre of Serbia, [†]First Surgical Clinic, [§]Clinic for Physical Medicine and Rehabilitation, ^{||}Department of Pathology, Belgrade, Serbia; University of Belgrade, Faculty of Medicine, [‡]Institute of Medical Statistics and Informatics, Belgrade, Serbia

Abstract

Background/Aim. Today, lymphatic metastases are only a relative contraindication for the surgical treatment of colorectal carcinoma (CRC). The aim of this study was to evaluate the effect of routine lymphadenectomy of the hepatic basin on the duration of the liver resection for CRC metachronous liver metastases. **Methods.** A total of 50 patients with CRC metachronous liver metastases underwent the liver resection with routine hepatic basin lymphadenectomy. **Results.** Larger volume of metastases (in mL), the number of affected segments, and the number of metastases as well the diameter of the largest lesion (in mm), determine the duration of the liver resection itself and the surgical procedure overall. The duration of lymphadenectomy was 25–55 min (32.2 min on average). **Conclusion.** Routine lymphadenectomy of the hepatic basin following the liver resection for CRC metachronous liver metastases, minimally prolongs the duration of the operation.

Key words:

colorectal neoplasms; liver; lymphatic metastasis; surgical procedures, operative; treatment outcome.

Apstrakt

Uvod/Cilj. Metastaze su u današnje vreme samo relativna kontraindikacija za hirurško lečenje kolorektalnog karcinoma (KRK). Cilj ove studije je bio da se utvrdi uticaj rutinske limfadenektomije hepatičnog sliva na trajanje resekcije jetre zbog metahronih jetrinih metastaza KRK. **Metode.** Ukupno 50 bolesnika sa metastazama jetre KRK podvrgnuto je resekciji jetre sa rutinskom limfadenektomijom hepatičnog sliva. **Rezultati.** Veći volumen metastaza jetre (u mL), broj zahvaćenih segmenata jetre, broj metastaza u jetri i veličina najveće metastaze u jetri (u mm) određivali su dužinu trajanja resekcije jetre i operacije u celini. Vreme trajanja limfadenektomije iznosilo je od 25 do 55 min (prosečno 32,2 min). **Zaključak.** Rutinska limfadenektomija hepatičnog sliva kod resekcije jetre zbog metahronih metastaza KRK neznatno produžava vreme trajanja operacije.

Ključne reči:

kolorektalne neoplazme; jetra; neoplazme, limfne metastaze; hirurgija, operativne procedure; lečenje, ishod.

Introduction

Malignant cells within the lymph nodes (LNs) of the hepatic basin, originate from the liver metastasis (remetastasis, metastasis from metastases, tertiary metastasis, lymphatic metastasis)^{1,2}. Remetastasis originate from lymphogenic dissemination of the metastatic liver disease³.

In the past, positive LNs of the hepatic basin were a contraindication for liver resection of metastases of colorec-

tal carcinoma (CRC). Today, lymphatic metastases are only a relative contraindication for the surgical treatment of CRC liver metastases⁴.

Macroscopically enlarged LNs are detected radiologically (preoperatively, perioperatively), visually, or by palpation (intraoperatively). The macroscopic examination of enlarged LNs was confirmed of malignancy in 2%–10% of patients (larger, hard or soft lymph node, pink or white) while the revealed malignancy range of 14%–30% surgically

treated patients⁵⁻⁸. However, only the histopathological examination can reliably confirm the presence of malignancy in the LNs by detecting the malignant cells⁹.

Based on the Japanese classification of gastric cancer and the General Rules for surgical and pathological studies of cancer of the biliary tract, Kokudo et al.⁴ classified the LNs of the hepatic basin into seven groups (Figure 1).

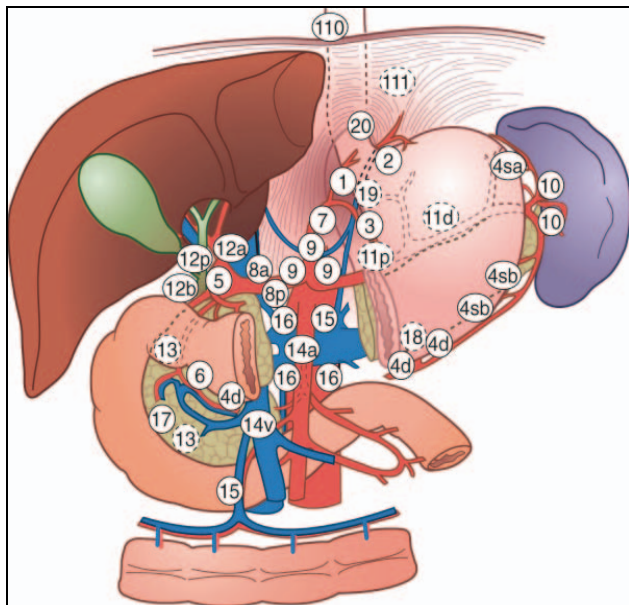


Fig.1 – Classification of lymph nodes (LNs) by group Gastric Cancer Association (JGCA)⁴.

LNs of the hepatic basin: 8a – anterosuperior LNs along the common hepatic artery, 8p – posterior LNs along the common hepatic artery, 12a – LNs along the proper hepatic artery, 12p – LNs along the portal vein, 12h – LNs of the liver hilum, 12b – LNs along the bile duct, 13 – LNs posterior of the pancreatic head.

The location and number of the LNs involved is a significant prognostic factor of survival for the operated patients^{4,9-14}.

Lymphadenectomy of the hepatic basin involves excision of the LNs around the hepatic pedicle – hepatoduodenal ligament (around the hilus of the liver, common bile duct, cystic duct, portal vein, hepatic artery), retropancreatic (posterior of the pancreatic head), and along the common hepatic artery (at its origin at the level of the celiac axis).

Lymphadenectomy can be standardized (around hepatic pedicle), or extensive^{4,10-12}. Standardized (localized) regional lymphadenectomy is limited lymphadenectomy in the area of the hepatic pedicle (hepatoduodenal ligament, retropancreatic, along the common hepatic artery)^{4,10-12}. Extended lymphadenectomy includes additional dissection of the LNs at the celiac axis (Group 9); however it does not affect survival significantly^{4,10-12}. The positive LNs at the celiac axis are a poor prognostic factor for survival, and there are no recommendations for extended lymphadenectomy^{4,10-12,15}.

Depending on the degree of dissection, lymphadenectomy can be routine, or based on the selection of the LNs. Routine lymphadenectomy involves the removal of all the LNs of the hepatic basin (pedicle), i.e., complete dissection along hepato-

duodenal and hepatogastric ligaments. In contrast to routine lymphadenectomy, a sampling of selected LNs includes their removal from the hepatic basin after macroscopic validation, by palpation or by imaging methods^{15,16}.

Selective lymphadenectomy is performed in strictly defined patients (young patients, with no comorbidities, or when chemotherapy options are exhausted or chemotherapy is not tolerated)¹⁷.

There are no randomized trials of liver resection for CRC metastases, with and without lymphadenectomy^{13,18}. However, existing reports vary with regards to the recommended extent of lymphadenectomy and the observed effects^{4,6,10,12,19}.

The prognostic significance of lymphadenectomy is that it facilitates early detection of recurrence^{20,21}. Detection of positive LNs leads to a timely administration of adjuvant chemotherapy, and it prolongs the survival^{4,18,22,23}.

Methods

This prospective study included the patients with CRC liver metastases who underwent surgery for primary CRC as well as the metachronous liver metastasis. The study includes 50 patients operated during a period ranging from 01.01.2015 to 01.07.2016, at the First Surgical Clinic, the Clinical Center of Serbia in Belgrade.

The inclusion criteria for the patients in this study were: the computed tomography (CT) or magnetic resonance imaging (MRI) verification of surgically treatable metachronous liver metastasis; complete resection of all metastatic lesions regardless of their number, size, and location, and complete regional lymphadenectomy of the hepatic basin.

The exclusion criteria were: the presence of extrahepatic and distant metastasis; the patients who underwent surgery for another carcinoma; the patients diagnosed with other types of cancer; the patients requiring multiple or combined resections of other organs; macroscopically identifiable malignant lymphadenopathy of the hepatic basin, without suspicion or evidence of other malignant lymphadenopathies.

Routine lymphadenectomy was performed as the dissection of the hepatoduodenal ligament, along the common hepatic artery and retropancreatically (according to the method of Moszkowicz et al.¹⁶). The following groups of hepatic basin lymph nodes were removed by routine lymphadenectomy: 8a, 8b, 12a, 12p, 12b, 12h, 13.

Clinical parameters of the patients with CRC and liver metastases

The demographic factors and comorbidity based on disease history are presented in the Table 1.

The surgical parameters of the study were the number, size, and location of the liver metastases; the number of affected liver segments; the selection of the surgical procedure – the liver resection (anatomical and nonanatomical, major or minor); the number of drains; and the duration of the postoperative drainage (Table 2).

Table 1

The demographic factors and comorbidity	
Parameter	Patients, n (%)
Sex	
men	35 (70.0)
women	15 (30.0)
Age (years)	
< 40	5 (10.0)
40–49	5 (10.0)
50–59	10 (20.0)
60–69	18 (36.0)
70–79	11 (22.0)
80–89	1 (2.0)
Comorbidity	
no	24 (48.0)
yes	26 (52.0)
ASA score	
1	10 (20.0)
2	28 (56.0)
3	12 (24.0)
Lymphadenopathy on CT/MRI	
no	43 (86.0)
yes	7 (14.0)
Volume of the liver (mL)	
1,000–1,499	28 (56.0)
1,500–1,999	15 (30.0)
2,000–2,499	7 (14.0)
Volume of liver metastases (mL)	
< 60	20 (40.0)
60–119	19 (38.0)
120–179	8 (16.0)
> 180	3 (6.0)
Chemotherapy before liver resection	
no	32 (64.0)
yes	18 (36.0)

ASA – American Society of Anaesthesiologists;
CT – computed tomography; MRI – magnetic resonance.

Results are presented using the descriptive statistics tools (measures of central tendency – an arithmetic mean; variability – the standard deviation; relative numbers) as well as the analytical statistical evaluation of the significance of the difference (parametric – *t* test; nonparametric – χ^2 test).

Results

The standard histopathological analysis detected 12% positive LNs of the hepatic basin (6 patients). The immunohistochemical analysis confirmed an additional 16% positive LNs (*n* = 8).

The postoperative complications following the liver resection with routine lymphadenectomy (nonspecific postoperative complications) were detected in 8 (16%) patients: the fluid collection at the site of liver resection – 3 (6%) patients, the abscess at the site of resection – 2 (4%) patients, the partial portal vein thrombosis, the biliary fistula and surgical wound infection each in one 1 (2%) patient.

The influence of selected parameters on the occurrence of postoperative complications after the liver resection following routine lymphadenectomy is shown in Table 3 and Table 4.

Table 2

The surgical parameters	
Parameter	Patients, n (%)
Number of liver metastases	
1	14 (28.0)
2	23 (46.0)
3 or more	13 (26.0)
Largest metastasis diameter (mm)	
< 20 mm	7 (14.0)
20–50 mm	26 (42.0)
> 50 mm	17 (34.0)
Lobar localisation of metastasis	
left	5 (10.0)
right	20 (40.0)
both	25 (50.0)
Number of the affected segments	
1	7 (14.0)
2	18 (36.0)
3 or more	25 (50.0)
Type of liver resection	
nonanatomical	27 (54.0)
anatomical	23 (46.0)
Size of liver resection	
small	25 (50.0)
large	25 (50.0)
Number of drains	
1	2 (4.0)
2	38 (76.0)
3 or more	10 (20.0)
Duration of the postoperative drainage (days)	
1–3	27 (54.0)
4–5	19 (38.0)
6 or more	

The features of postoperative complications following routine lymphadenectomy are shown in Table 5 and Table 6.

Routine lymphadenectomy of the hepatic basin performed in the Belgrade First Surgical Clinic is shown in the Figure 2. The duration of lymphadenectomy was 25–55 min (average 32.2 min).

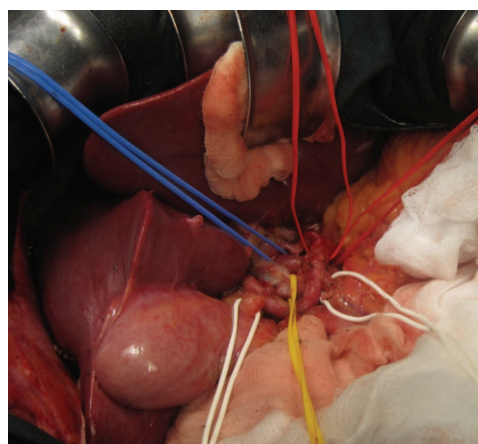


Fig. 2 – Routine lymphadenectomy of the hepatic basin (First Surgical Clinic, VII Department).

Table 3
The influence of selected parameters on the occurrence of postoperative complications after the liver resection following routine lymphadenectomy

Parameter	Postoperative complications		<i>p</i> -value (χ^2 test)
	No n (%)	Yes n (%)	
Sex			
men	27 (77.1)	8 (22.9)	0.086
women	15 (100.0)	0 (0.0)	
Chemotherapy before liver resection			
no	27 (84.4)	5 (15.6)	1.000
yes	15 (83.3)	3 (16.7)	
Comorbidity			
no	18 (75.0)	6 (25.0)	0.132
yes	24 (92.3)	2 (7.7)	
ASA score			
1	7 (70.0)	3 (30.0)	0.567
2	25 (89.3)	3 (10.7)	
3	10 (83.3)	2 (16.7)	
Lymphadenopathy seen on imaging (CT/MRI)			
no	37 (86.0)	6 (14.0)	0.580
yes	5 (71.4)	2 (28.6)	
Type of liver resection			
nonanatomical	24 (88.9)	3 (11.1)	0.444
anatomical	18 (78.3)	5 (21.7)	
Size of liver resection			
small	19 (76.0)	6 (24.0)	0.247
large	23 (92.0)	2 (8.0)	
Lobar localisation of metastases			
left	5 (100.0)	0 (0.0)	0.668
right	16 (80.0)	4 (20.0)	
both	21 (84.0)	4 (16.0)	

n – number of patients; **CT** – computed tomography; **MRI** – magnetic resonance imaging; **ASA** – American Society of Anesthesiologists

Table 4
The influence of selected parameters as a function of their mean value, on the occurrence of postoperative complications after the liver resection following routine lymphadenectomy

Parameter	Postoperative complications		<i>p</i> value
	n	mean \pm SD	
Age			
no	42	60.64 \pm 11.25	0.344 ^a
yes	8	57.25 \pm 10.25	
Chemotherapy before the liver resection			
no	15	5.20 \pm 2.11	0.933 ^b
yes	3	4.67 \pm 1.15	
Volume of the liver (mL)			
no	42	1,542.90 \pm 340.14	0.904 ^a
yes	8	1,518.25 \pm 325.07	
Volume of CRC metastases of (mL)			
no	42	71.69 \pm 45.31	0.019 ^b
yes	8	122.75 \pm 57.63	
Number of drains			
no	42	2.14 \pm .47	0.105 ^b
yes	8	2.50 \pm .93	
Duration of postoperative drainage (days)			
no	42	5.52 \pm 2.76	0.015 ^b
yes	8	11.25 \pm 8.71	
Number of the affected segments			
no	42	2.79 \pm 1.34	0.567 ^b
yes	8	2.50 \pm 0.93	
Number of hepatic metastases			
no	42	2.98 \pm 2.05	0.759 ^b
yes	8	2.63 \pm 1.69	
Size of the largest metastasis (mm)			
no	42	39.40 \pm 22.59	0.031 ^b
yes	8	70.50 \pm 38.81	

n – number of patients; **SD** – standard deviation; ^a*t*-test, ^bMann-Whitney *U* test.

Table 5

The occurrence of postoperative complications as a function of the duration of routine lymphadenectomy and the liver resection

Postoperative complications	n	mean \pm SD	p value (t-test)
Duration of routine lymphadenectomy (min)			
no	42	32.26 \pm 7.00	0.890
yes	8	31.88 \pm 3.72	
Duration of liver resection (min)			
no	42	123.10 \pm 53.35	0.011
yes	8	175.00 \pm 47.21	

n – number of patients; SD – standard deviation.

Table 6

The frequency and distribution of postoperative complications following routine lymphadenectomy

Authors	Year	Number of patients	Type of lymphadenectomy	Postoperative complications	Type of postoperative complication
Yuasa et al. ³¹	1994	52	Extended	42%	Stenosis or occlusion of hepatic artery
Elias et al. ⁵	1996	100	Extended	17%	Biliary fistula Pulmonary effusion
Kokudo et al. ⁴	1999	160	Routine	/	Lymphorrhoea, Stenosis of bile duct
Jaeck et al. ¹⁰	2002	221	Routine	/	Lymphorrhoea, Biliary complications
Ercolani et al. ³³	2004	120	Routine	0.83%	Bleeding
Moszkowicz et al. ¹⁶	2012	76	Routine	/	Pancreatic fistula Lymphorrhoea Bleeding, ischemia Biliary fistula

Discussion

Some authors have demonstrated a beneficial effect of routine lymphadenectomy added to the liver resection in prolonging the five-year survival over 30%^{4, 9, 10, 18, 24–26}.

Routine hilar lymphadenectomy was performed by 27% of the surgeons, with the same percentage of surgeons who made the sampling of selected lymph nodes⁴.

Numerous studies indicate that the dissection of lymph nodes of the hepatic basin reveals a higher frequency of the micrometastasis than detectable macroscopically, or by palpation^{4–6, 9, 12, 15, 16, 26–28}.

Gallinger et al.²⁹ and Bradatsch et al.³⁰ argue that if lymphadenopathy is not confirmed by imaging methods (ultrasound, CT, MRI), it is not necessary to perform routine lymphadenectomy because it prolongs surgery and increases the incidence of postoperative complications³¹, although the postoperative complications are rare and relatively mild^{5, 10}.

The postoperative complications, following the liver resection with routine lymphadenectomy include: stenosis of the hepatic artery, postoperative bleeding, lymphorrhoea, biliary complications, pancreatic fistula^{4, 5, 16, 31–33}.

All postoperative complications in our study were non-specific and managed conservatively (percutaneous drainage,

antibiotic therapy, endoscopic retrograde cholangiopancreatography – ERCP), which is in accordance with the published results. The liver resection for CRC metastasis was prolonged by adding lymphadenectomy for 20 \pm 12.5 min, without mortality in the study²³. The authors suggest performing routine lymphadenectomy associated with the liver resection because there are no reliable methods for the confirmation of the presumed malignant lymphadenopathy within the hepatic basin based on CT imaging and intraoperative examination²³.

The surgical duration of lymphadenectomy in this study ranged from 25–55 min (average 32.2 min). The duration was gradually decreased over time as a result of improvement in surgical techniques.

Conclusion

The larger volume of liver metastases (mL), the number of the affected segments, the number of metastasis and the diameter of the largest lesion (mm) prolong the duration of liver resection itself and duration of the entire operation.

Routine lymphadenectomy of the hepatic basin, following the liver resection for CRC metastases, minimally prolongs the duration of the operation.

R E F E R E N C E S

1. August DA, Sugarbaker PH, Schneider PD. Lymphatic dissemination of hepatic metastases. Implications for the follow-up and treatment of patients with colorectal cancer. *Cancer* 1985; 55(7): 1490–4.
2. Lefor AT, Hughes KS, Shiloni E, Steinberg SM, Vetto JT, Papa MZ, et al. Intra-abdominal extrahepatic disease in patients with colorectal hepatic metastases. *Dis Colon Rectum* 1988; 31(2): 100–3.
3. Rosai J. Colon. In: Rosai J, editor. *Rosai and Ackerman's Surgical Pathology*. 9th ed. Philadelphia: Mosby; 2004. p. 776–855.
4. Kokudo N, Sato T, Seki M, Ohta H, Azeкура K, Ueno M, et al. Hepatic lymph node involvement in resected cases of liver metastases from colorectal cancer. *Dis Colon Rectum* 1999; 42(10): 1285–90; discussion 1290–1.
5. Elias D, Saric J, Jaeck D, Arnaud JP, Gayet B, Rivoire M, et al. Prospective study of microscopic lymph node involvement of the hepatic pedicle during curative hepatectomy for colorectal metastases. *Br J Surg* 1996; 83(7): 942–5.
6. Gurusamy KS, Imber C, Davidson BR. Management of the Hepatic Lymph Nodes during Resection of Liver Metastases from Colorectal Cancer. A Systematic Review. *HPB Surgery* 2008; 2008: 684150.
7. Scheele J, Stangl R, Altendorf-Hofmann A, Gall FP. Indicators of prognosis after hepatic resection for colorectal secondaries. *Surgery* 1991; 110(1): 13–29.
8. Lupinacci RM, Paye F, Coelho FF, Kruger JA, Herman P. Lymphatic drainage of the liver and its implications in the management of colorectal cancer liver metastases. *Updates Surg* 2014; 66(4): 239–45.
9. Beckurts KT, Hölscher AH, Thorban S, Bollschweiler E, Siewert JR. Significance of lymph node involvement at the hepatic hilum in the resection of colorectal liver metastases. *Br J Surg* 1997; 84(8): 1081–4.
10. Jaeck D, Nakano H, Bachellier P, Inoue K, Weber J, Oussoultzoglou E, et al. Significance of hepatic pedicle lymph node involvement in patients with colorectal liver metastases: A prospective study. *Ann Surg Oncol* 2002; 9(5): 430–8.
11. Elias D, Onellet JF, Bellon N, Pignon JP, Pocard M, Lasser P. Extrahepatic disease does not contraindicate hepatectomy for colorectal liver metastases. *Br J Surg* 2003; 90(5): 567–74.
12. Laurent C, Sa Cunha A, Rullier E, Smith D, Rullier A, Saric J. Impact of microscopic hepatic lymph node involvement on survival after resection of colorectal liver metastasis. *J Am Coll Surg* 2004; 198(6): 884–91.
13. Bennett JJ, Schmidt CR, Klimstra DS, Grobmyer SR, Ishill NM, D'Angelica M, et al. Perihepatic lymph node micrometastases impact outcome after partial hepatectomy for colorectal metastases. *Ann Surg Oncol* 2008; 15(4): 1130–6.
14. Nakamura S, Yokoi Y, Suzuki S, Baba S, Muro H. Results of extensive surgery for liver metastases in colorectal carcinoma. *Br J Surg* 1992; 79(1): 35–8.
15. Gibbs JF, Weber TK, Rodriguez-Bigas MA, Driscoll DL, Petrelli NJ. Intraoperative determinants of unresectability for patients with colorectal hepatic metastases. *Cancer* 1998; 82(7): 1244–9.
16. Moszkowicz D, Cauchy F, Dokmak S, Belghiti J. Routine Pedicular Lymphadenectomy for Colorectal Liver Metastases. *J Am Coll Surg* 2012; 214(6): 39–44.
17. Koti RS, Simillis C, Gurusamy KS, Jaconides M, Davidson BR. Management of the Hepatic Lymph Nodes During Resection of Liver Metastases from Colorectal Cancer: A Systematic Review. *Curr Colorectal Cancer Rep* 2013; 9(2): 203–12.
18. Lupinacci RM, Coelho FF, Kruger J, Perini MV, Herman P. Hilar Lymph Node Involvement in Colorectal Cancer Liver Metastases – An Overview. *J Gastroint Dig Syst* 2011; S6: 002.
19. Hadden WJ, Rewer PR, Brown K, Mittal A, Samra JS, Hugh TJ. Resection of colorectal liver metastases and extra-hepatic disease: A systematic review and proportional meta-analysis of survival outcomes. *HPB (Oxford)* 2016; 18(3): 209–20.
20. Suzuki H, Fujii T, Asao T, Tsutsumi S, Wada S, Araki K, et al. Extracapsular lymph node involvement is associated with colorectal liver metastases and impact outcome after hepatectomy for colorectal metastases. *World J Surg* 2014; 38(8): 2079–88.
21. Nanji S, Tsang ME, Wei X, Booth CM. Regional lymph node involvement in patients undergoing liver resection for colorectal cancer metastases. *Eur J Surg Oncol* 2017; 43(2): 322–9.
22. Grobmyer SR, Wang L, Gonen M, Fong Y, Klimstra D, Angelica MD, et al. Perihepatic lymph node assessment in patients undergoing partial hepatectomy for malignancy. *Ann Surg* 2006; 244(2): 260–4.
23. Rau C, Blanc B, Ronot M, Dokmak S, Aussilhou B, Faivre S, et al. Neither preoperative computed tomography nor intra-operative examination can predict metastatic lymph node in the hepatic pedicle in patients with colorectal liver metastasis. *Ann Surg Oncol* 2012; 19(1): 163–8.
24. Carpio DR, D'Angelica M. Liver resection for metastatic colorectal cancer in the presence of extrahepatic disease. *Ann Surg Oncol* 2009; 16(9): 2411–21.
25. Ishibashi K, Ishida H, Ohsawa T, Okada N, Kumamoto K, Haga N. Impact of hepatic lymph node metastasis on survival of patients with synchronous resectable or unresectable liver metastases of colorectal cancer. *Tech Coloproctol* 2013; 17(1): 51–7.
26. Fong Y, Fortner J, Sun RL, Brennan MF, Blumgart LH. Clinical score for predicting recurrence after hepatic resection for metastatic colorectal cancer: Analysis of 1001 consecutive cases. *Ann Surg* 1999; 230(3): 309–18.
27. Rodgers MS, McCall JL. Surgery for colorectal liver metastases with hepatic lymph node involvement: A systematic review. *Br J Surg* 2000; 87(9): 1142–55.
28. Liu W, Yan X, Wang K, Bao Q, Sun Y, Xing B. The outcome of liver resection and lymphadenectomy for hilar lymph node involvement in colorectal cancer liver metastases. *Int J Colorectal Dis* 2014; 29(6): 737–45.
29. Gallinger S, Biagi JJ, Fletcher GG, Nhan C, Ruo L, McLeod RS. Liver resection for colorectal cancer metastases. *Curr Oncol* 2013; 20(3): e255–65.
30. Bradatsch A, Kornprat P, Bacher H, Cervenka H, Haybaeck J, Mischinger H. The Value of Lymph Node Dissection in the Surgery of Colorectal Cancer Liver Metastases. *Anticancer Res* 2016; 36(6): 2993–7.
31. Yuasa N, Nimura Y, Hayakawa N, Kamiya J, Kondo S, Nagino M. Angiographic changes in the hepatic artery after skeletonization resection for biliary tract cancer. *Br J Surg* 1994; 81(4): 591–4.
32. Viana EF, Herman P, Siqueira SC, Taka T, Carvalho P, Coelho FF, et al. Lymphadenectomy in colorectal cancer liver metastases resection: Incidence of hilar lymph nodes micrometastasis. *J Surg Oncol* 2009; 100(7): 534–7.
33. Ervolani G, Grazi GL, Ravaioli M, Grigioni WF, Cescon M, Gardini A, et al. The role of lymphadenectomy for liver tumors: Further considerations on the appropriateness of treatment strategy. *Ann Surg* 2004; 239(2): 202–9.

Received on July 20, 2017.

Revised on September 21, 2017.

Accepted on October 09, 2017.

Online First October, 2017.